



Article title: Headache Associated with Chiari Malformation Type One

Authors: yasser seddeg[1], Ali Awad [2], Haytham Osman[3]

Affiliations: associate professor-faculty of medicine-the national ribat university[1], Neurosurgery Department National Ribat University teaching hospital[2], Neurosurgery Department National Ribat University[3]

Orcid ids: 0000-0003-4494-0515[1], 0000-0002-3389-0201[3]

Contact e-mail: yasseranatomy@gmail.com

License information: This work has been published open access under Creative Commons Attribution License <http://creativecommons.org/licenses/by/4.0/>, which permits unrestricted use, distribution, and reproduction in any medium, provided the original work is properly cited. Conditions, terms of use and publishing policy can be found at <https://www.scienceopen.com/>.

Preprint statement: This article is a preprint and has not been peer-reviewed, under consideration and submitted to AfricArXiv Preprints for open peer review.

Links to data: ribat.edu.sd

DOI: 10.14293/111.000/000002.v2

Preprint first posted online: 20 August 2020

Keywords: Chiari malformation , CM-1, Headache, occipital headache, neck pain

Headache associated with Chiari Malformation Type One

Yasser Seddeg Abdulghani¹, Ali Awad Ali², Haythem Hussain Mohamed Osman²

¹ Associate professor- Anatomy department- faculty of medicine-The National Ribat University-Khartoum-Sudan

² Neurosurgery department -faculty of medicine-the National Ribat University-Khartoum-Sudan

Correspondence author:

Yasser Seddeg Abdulghani, MBBS, MSc, PhD

Associate professor- Anatomy department- faculty of medicine-The National Ribat University-Khartoum-Sudan

Email yasseranatomy@gmail.com

Mobile 00249912670747

Abstract

Background:

Patients with chiari malformation type one (CM -1) headache may be mistaken by chronic migraines or other causes of headache, so analysis of headache related to CM-1 is corner stone in early diagnosis of the disease.

OBJECTIVE:

The purpose of this study was to assess the frequency and clinical characteristics of headache in the patients with CM-1 to help primary care clinicians better understand the relationship between an individual's presenting symptoms of CM1. 1 so aiding for early diagnosis and early management and for better outcome.

METHODS:

This was prospective observational analytical study carried out in Khartoum state hospitals that provide neurosurgical services, (NCNS, Neurospine Center-Ribat Teaching Hospital, Military Hospital, and Omdurman Teaching Hospital) from February 2018- September 2019. Study was included 18 adult males and females of different ages diagnosed with Chiari MF -1 who undergoing decompressive surgery.

Symptomatic patients diagnosed with Chiari MF -1Patients with no history of neurological illnesses or history of cranial surgery were included.

Patients with History of any neurological diseases such as multiple sclerosis and with other causes of headache were excluded from the study.

Evaluation and full analysis of headache were registered including type of headache, site, duration headache, time lasting, radiation of pain, severity using headache scale, associated ocular and visual symptoms.

RESULTS:

This study included 18 patients diagnosed with chiari 1 malformation and suffering from headache related to chiari 1. Full analysis of the headache was obtained. The headache was

mostly in the back of the head (n=17/18 , 94.4%) and only in (n=1/18, 5.6%), the headache was in the sides or front of the head. In 12 patients (n=12/18 , 66.7%) headache worsen by bending forward. And in 6 patients (n=6/18 , 33.3%) worsen by cough. Regarding the type of headache, mostly pressure in nature (n=17/18 , 94.4%) and it was rarely throbbing in nature(n=1/18, 5.6%),. All patients were asked to evaluate their headache in headache scale from 1 to 10 (10 more severe). The scale ranged between 5 and 9 with mean 6.88. headache could be long or short lasting (from hours to days).Eye symptoms included blurring of vision complained by 9 patients(n=9/18, 50%), light sensitivity in 5 patients ((n=5/18, 27.8%), and 6 patients (n=6/18 , 33.3%) there were no eye symptoms. Neck pain was a dominant symptom seen in 17 patients (n=17/18, 94.4%) , and back pain in 18 patients (n=18/18 , 100%) . headache subsided after decompression surgery in all patients included in this study.

CONCLUSIONS:

Knowledge and understanding the CM-1 headache characters are important for early diagnosis and early treatment of the disease.

Key Words:

Chiari malformation , CM-1, Headache, occipital headache, neck pain

Introduction:

Headaches are one of the most common medical complaints; most people experience them at some point in their life. They can affect anyone regardless of age and gender^[1].

The World Health Organization (WHO) reports that almost half of all adults worldwide will experience a headache in any given year ^[2].

A headache can be a sign of stress or emotional distress, or it can result from a medical disorder, such as migraine or high blood pressure, anxiety, or depression. It can lead to other problems. People with chronic migraine headaches may find it hard to attend work or school regularly ^[1, 2].

Patients with Chiari I malformation either with or without syringomyelia often complain of headache. Whether its throbbing in the back of the head (suboccipital), pressure behind the eyes, or brought on by coughing, crying, or singing, the majority - but not all - of Chiari patients suffer from some type of headache. One such headache which seems to be common among Chiari patients are migraines ^[3].

Migraines refer to severe headaches, which usually recur, and can include changes in vision , aura . Unfortunately, when a person with migraines and Chiari seeks help from a doctor, the migraines can become the focus of treatment since they are more common. This can mask the underlying Chiari problem and delay an accurate diagnosis and treatment. So, put in minds the chiari headache characters help in early diagnosis and treatment of this disease^[4].

Chiari malformation (CM) is a hindbrain disorder that is associated with deformity and elongation of the cerebellar tonsils. It is specifically characterized by the descent of the cerebellar tonsils >5 mm below the foramen magnum into the spinal canal [5]. There are four types of Chiari malformations described in the literature. Due to the fact that it is a common finding in neurosurgery practice, Chiari 1 malformation was also called Chiari anomaly, while Chiari 2 malformation is usually associated with myelomeningocele. Chiari 3 and 4 malformations are extremely rare pathologies and are usually fatal [3]. Although CM-I occurs in pediatric and adult patients, the prevalence of CM-I in Sudan is not well defined. CM-I often becomes clinically apparent when the patient is aged 20–39 years. Thus, in the past, CM-I had been diagnosed primarily during adolescence or adulthood. With the advent of magnetic resonance imaging (MRI), however, the number of pediatric patients diagnosed with CM-I is increasing due to imaging facilities [5].

The most common symptom associated with a Chiari malformation is occipital headaches. These headaches are felt near the base of the skull and may radiate to cause pain in the neck and shoulders. They can be severe and may be described as sharp, brief, throbbing or pulsating. Occipital headaches can be brought on or worsened by coughing, straining or sneezing.

Abnormalities affecting the eyes can also affect individuals with a Chiari malformation including double vision (diplopia), abnormal sensitivity to light (photophobia), blurred vision, involuntary eye movements (nystagmus) and pain behind the eyes. Vertigo, dizziness, ringing in the ears (tinnitus) and bilateral hearing impairment can also develop [6].

Table 1 below shows the Diagnostic criteria for headaches caused by type I Chiari malformation according to the International Headache Society criteria [7]:

Diagnostic criteria for type I Chiari malformation headache [7].

A. Headache fulfilling at least 1 of the following conditions as well as condition B:
1. Triggered by cough and/or Valsalva maneuvers
2. Prolonged occipital and/or suboccipital headache (lasting hours to days)
3. Associated with signs or symptoms of cerebellar, brainstem, or cervical spinal cord dysfunction
B. Headache resolves within 3 months of successful treatment of the Chiari malformation

CM 1 has a variety of presentation with headache being the most common symptom. The evaluation and treatment of headache related to CM 1 are often difficult, because the pain in the occipital-suboccipital region or headache that is of cough-type suggests symptomatic CM 1, but patients suffering from CM 1 can also report migraine or tension-type headache.

In Sudan, most of the CM 1 patients come after their symptoms progressed to advanced levels, myelopathy or symptoms related to syrinx and hydrocephalus, due to delayed diagnosis because the neurosurgery service is only provided in 2 major cities in Sudan with low diagnostic resources. So most of CM 1 headache is treated initially as migraine or other types of headache. The aim of this study was to increase the awareness of physicians and health providers regarding CM 1 related headache to help in early diagnosis and treatment of the disease.

Patients and methods:

This was prospective observational analytical study carried out in Khartoum state hospitals that provide neurosurgical services, (NCNS, Neurospine Center-Ribat Teaching Hospital, Military Hospital, and Omdurman Teaching Hospital) from February 2018- September 2019. Study was included 18 adult males and females of different ages diagnosed with Chiari MF -1 who undergoing decompressive surgery.

Symptomatic patients diagnosed with Chiari MF -1Patients with no history of neurological illnesses or history of cranial surgery were included.

Patients with History of any neurological diseases such as multiple sclerosis and with other causes of headache were excluded from the study.

Evaluation and full analysis of headache were registered including type of headache, site, duration headache, time lasting, radiation of pain, severity using headache scale, associated ocular and visual symptoms. Post surgical follow up was done and re-evaluation of symptoms was obtained. Data was analyzed using SPSS version 20 and the results were shown in tables and graphs.

Ethical approval:

All patients included in this study were consented and the purposes of the study were explained to them to share in this study. The National Ribat University Ethics Committee gave overall approval of the protocol. Further approvals were obtained from the Ethics Committee of Sudan Medical Specialization Board and hospitals where study carried on.

Results:

The total number of patients included was 18 in whom 10 were males and 9 were females. With age ranged between 17 years and 46 years with mean age of 33.45 +/- 10.14.

This study included 18 patients diagnosed with chiari 1 malformation and suffering from headache related to chiari 1. Full analysis of the headache was obtained. The headache was mostly in the back of the head (n=17/18 , 94.4%) and only in one patient (n=1/18, 5.6%), the headache was in the sides of the head. In 12 patients (n=12/18 , 66.7%) headache worsen by bending forward. And in 6 patients (n=6/18 , 33.3%) worsen by cough. Regarding the type of headache, mostly pressure in nature (n=17/18 , 94.4%) and it was rarely throbbing in nature(n=1/18, 5.6%),. All patients were asked to evaluate their headache in headache scale from 1 to 10 (10 more severe). The scale ranged between 5 and 9 with mean 6.88. headache could be long or short lasting (from hours to days).Eye symptoms included blurring of vision complained by 9 patients(n=9/18, 50%), light sensitivity in 5 patients ((n=5/18, 27.8%), and 4 patients (n=4/18 , 22.2%) there were no eye symptoms. Neck pain was a dominant symptom seen in 17 patients (n=17/18, 94.4%) , and back pain in 18 patients (n=18/18 , 100%) . headache subsided after decompression surgery in all patients included in this study.

Fourteen patients (n=14/18, 77.8%) had relatively long-lasting attacks ranging from 3 hours to several days; 4 patients (n=4/18, 22.2%) had continuous, fluctuating headaches.

Tables and figures below summarize the headache analysis among the study group:

Table 2: Site of headache among CM 1 study group: (n=18)

Site of Headache	Frequency	Percent
Back of the head	17	94.4%
Side of the head	1	5.6%
Total	18	100%

Table 3: Aggravating factors of headache among CM 1 study group : (n=18)

Headache worse by:	Frequency	Percent
Bending forward	12	66.7%
Cough and sneezing	6	33.3%
Total	18	100%

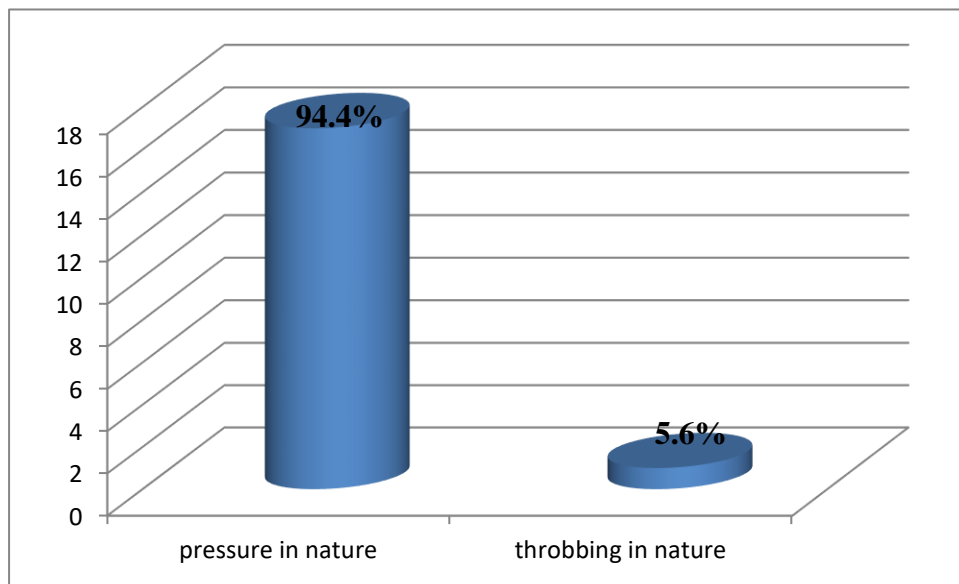


Figure 1 : Nature of headache among CM 1 study group. (n=18)

Table 4: Presence of light sensitivity among CM 1 study group : (n=18)

Light sensitivity	Frequency	Percent %
Light sensitivity	5	27.8
Blurring of vision	9	50.0
no eye symptoms	4	22.2
Total	18	100

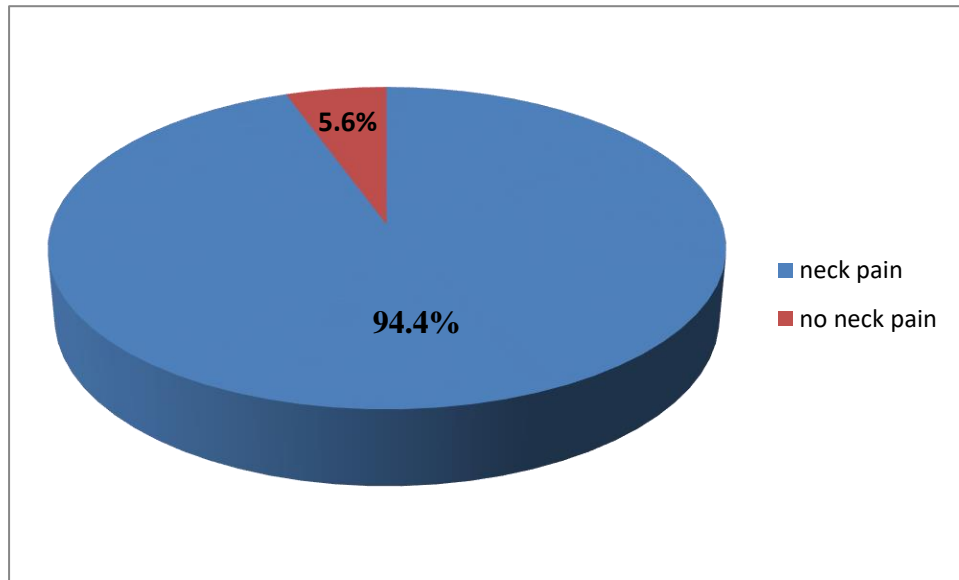


Figure 2: Neck pain among CM 1 study group. (n=18)

Table 5: Mean duration , days of attack per month, and time lasting of the headache among the CM 1 study group :

	Mean time (n=18)
Duration of headache	7 months
Days per month	23 days
Lasting time per attack	20 minutes

Table 6: Summary of characteristics of CM 1 Headache (n=18) :

Symptoms	Percent
Occipital headache	94.4%
Pressure or crushing in nature	94.4%
Of any duration (Long lasting or short lasting)	100%
Most days of the month	100%
Ocular pressure pain	66%
Pain worse by valsalva or bending forward	66.7%
Neck pain or heaviness	94.4%
Shoulder pain and heaviness or back pain	100%
Light sensitivity or blurring vision	77.8%

Discussion:

Most of the headache among the study group was in the back of the head. And was pressure in nature. The severity of headache differs between patients. Headache was associated with eye symptoms included light sensitivity and blurring of vision.

A headache that is specific to posterior fossa crowding and CMI, occipital-suboccipital pain,. Valsalva headache maneuvers may be due to cranial nerves or upper cervical nerves stimulation. ocular vestibule symptoms suggest a pseudo tumor-like condition; or CSF dynamic disturbances.

What is the cause of headache in CM-1 stills debatable, The structural abnormalities in CM-1 may include stretching of cranial nerves or direct compression of brain stem nuclei, compression of the posterolateral part of the medulla and the upper cervical spinal cord, vascular distortion in the territories irrigated by the vertebral and posterior inferior cerebellar arteries, and pressure on the rootlets of C1, C2, and the vagus nerves^[8].

Headache being frequently seen in daily clinical practice, CM-1 related headache may be underestimated or missed by other types of headache like migraine or cluster headaches. Focusing in detailed headache history and analysis may help improving the early diagnosis of different causes of headache including CM-1.

Two old previous studies were performed to analyze the headache associated with CM-1. The results of the present study were in consistence with the results done before but with fewer number of patients.

Stovner ^[9] reported on 34 patients with CMI; 20 reported headache (59%). Ten (50%) had short-lasting attacks of “cough headache” that lasted for less than 5 minutes. Fourteen of 20 (70%) had relatively long-lasting attacks ranging from 3 hours to several days; eight patients had continuous, fluctuating headaches. The relatively long lasting headaches were unilateral, without described location, and were pulsating in 50% of the patients, with side shift in four of seven patients. In those with continuous headache, seven of eight were in the posterior part of the head, half bilateral and half unilateral. Unlike cough headache, the protracted headaches were usually not precipitated by Valsalva-like maneuvers. Intermittent dizziness in 13 of 14 of the patients with long-lasting attacks was the most distinguishing feature in the patients with Chiari, differentiating them from cervicogenic headaches, which they otherwise resembled. Only three of 14 would be diagnosed with cervical headache according to standard criteria.

Milhorat et al ^[10] also observed 364 patients; 296 (81%) had headache. They reported that all experienced suboccipital headaches were described as a heavy, crushing, or pressure-like sensation that radiated to the vertex, behind the eyes, and inferiorly to the neck and shoulders. Severe headaches were pounding, but non throbbing. A distinctive feature of the headaches was their tendency to be accentuated by physical exertion, Valsalva maneuvers, and sudden changes in posture.

From the results of this study and previous ones, headache associated with CM-1 is characteristic. Early diagnosis and early treatment can prevent development of more critical cerebellar, brainstem, or cervical symptoms and can stop the progression of the CM 1.

Conclusions

Understanding the CM-1 headache characters is important for early diagnosis and early treatment of the disease.

References:

1. World Health Organization . Headache disorders and public health. Education and management implications. Geneva: WHO; 2000. [[Google Scholar](#)]
2. World Health Organization . The World Health Report 2001. Geneva: WHO; 2001. [[Google Scholar](#)]
3. Sansur CA, Heiss JD, DeVroom HL, Eskioglu E, Ennis R, Oldfield EH. Pathophysiology of headache associated with cough in patients with Chiari I malformation. J Neurosurg. 2003 Mar;98(3):453-8. [[Google Scholar](#)] [[PubMed](#)]
3. Stovner L, Hagen K, Jensen R, Katsarava Z, Lipton R, Scher A, Steiner T, Zwart JA. The Global burden of headache: a documentation of headache prevalence and disability worldwide. Cephalalgia. 2007;27:193–210. doi: 10.1111/j.1468-2982.2007.01288.x. [[PubMed](#)] [[Google Scholar](#)]
4. Kaplan Y, Oksuz E, Chronic migraine associated with the Chiari type 1 malformation, Clin Neurol, Neurosurg (2008), doi:10.1016/j.clineuro.2008.05.016[[Google Scholar](#)] [[PubMed](#)]
5. Yasser Seddeg Abdulghani, Mohammed Awad Elzain, Ali Awad Ali, Haytham Hussien Mohamed, Basheer Mohammed Basheer Chiari type-I malformation: Clinical features and surgical outcome assessment using Chicago Chiari Outcome Score (CCOS) among Sudanese patients. Pak J Surg 2019; 35(4):325-30[[Google Scholar](#)]
6. Milhorat TM, Nishikawa M, Kula RW, Dlugacz YD. Mechanisms of cerebellar tonsil herniation in patients with Chiari malformations as a guide to clinical management. Acta Neurochir. 2010;152:1117-1127. [[PubMed](#)] [[Google Scholar](#)]
7. The International Classification of Headache Disorders 3rd edition <https://ichd-3.org/>

8. Domitrz I, Gawel M, Maj E. Cluster headache a symptom of different problems or a primary form?. A case report. *Neurol Neurochir Pol.* 2013;47:184–188. [PubMed] [Google Scholar]

9. Stovner LJ (1993) Headache associated with Chiari type I malformation. *Headache* 33:175–181 [PubMed] [Google Scholar]

10. Milhorat TH, Chou MW, Trinidad EM et al (1999) Chiari I malformation redefined: clinical and radiographic findings for 364 symptomatic patients. *Neurosurgery* 44(5):1005–1017 [PubMed] [Google Scholar]